

Durham Research Online

Deposited in DRO:

19 June 2012

Version of attached file:

Published Version

Peer-review status of attached file:

Peer-reviewed

Citation for published item:

Meenakshi, S. and Manjunath, K. Y. (2008) 'The tendinous intersections of rectus abdominis muscle.', *Journal of Mahatma Gandhi Institute of Medical Sciences.*, 13 (1). pp. 34-39.

Further information on publisher's website:

<http://medind.nic.in/jaw/t08/i1/jawt08i1c.shtml>

Publisher's copyright statement:

Additional information:

Use policy

The full-text may be used and/or reproduced, and given to third parties in any format or medium, without prior permission or charge, for personal research or study, educational, or not-for-profit purposes provided that:

- a full bibliographic reference is made to the original source
- a [link](#) is made to the metadata record in DRO
- the full-text is not changed in any way

The full-text must not be sold in any format or medium without the formal permission of the copyright holders.

Please consult the [full DRO policy](#) for further details.

THE TENDINOUS INTERSECTIONS OF RECTUS ABDOMINIS MUSCLE

S MEENAKSHI , KY MANJUNATH ***

ABSTRACT

Aim of the study : To identify the variations of the location and patterns of the tendinous intersections of rectus abdominis muscle in the cadavers as a guide to the surgical procedures.

Material and Methods : The number of the tendinous intersections of the rectus abdominis were studied in 41 cadavers (82 recti). The dimensions of the recti and the location and pattern of the tendinous inscriptions were studied only in 18 cadavers (36 recti).

Results : The number of tendinous intersections varied from one to four and their frequency of occurrence was as follows : four tendinous intersections - 18 cases (21.95%); three tendinous intersections-50 cases (60.97 %); two tendinous intersections - 12 cases (14.63%) and with only one inscription- two cases (2.44%).

Conclusions : Since location and patterns of the tendinous inscription varies from one study to the other, more extensive studies are required to establish a definite pattern among local populations.

Key Words : Rectus Abdominis; Rectus muscle of Abdomen; Surgical Flaps, TRAM Flaps.

Introduction :

The rectus muscle is quite often encountered by the surgeon during the surgery of the anterolateral wall of the abdomen.¹ The lesions of the rectus muscle can mimic acute intra abdominal conditions.² The muscle fibers of rectus abdominis are interrupted by three fibrous bands or tendinous intersections : one is usually situated at the level of the umbilicus, another opposite the free end of the xiphoid process, and a third about midway between the other two. These intersections pass transversely or obliquely across the muscle in a zigzag manner; they are rarely full thickness and may only extend

** Chelmsford, Essex, CM 1 7HL, UK. * Asso. Professor, Dept. of Anatomy, St. John's Medical College, Bangalore - 560034.

Address for correspondence - Dr. Manjunath KY, Asso. Prof., Department of Anatomy, St. John's Medical College, Bangalore - 560034.

half-way through. They adhere closely to the anterior lamina of the sheath of the muscle. Sometimes one or two incomplete intersections are present below the umbilicus. The intersections may occur secondarily during development, but one controversial suggestion is that they represent the myosepta delineating the myotomes that form the muscle.^{1,3,4} The rectus abdominis (RAM) flap is being frequently used in reconstructive surgery. Knowledge concerning the variations of the tendinous intersections of the rectus abdominis has become important to the surgeons in planning a transverse rectus muscle (TRAM) flap for surgical reconstruction.

In this present study, frequency of occurrence of tendinous intersections in rectus abdominis muscle as observed in dissection room cadavers is reported.

Material and Methods :

Material for this study consisted of 41 formalin fixed dissection room cadavers of South Indian origin (27 males and 14 females) allotted to undergraduate students for dissection. In each case following the skin reflection, the rectus sheath was opened by a vertical incision bilaterally and the tendinous intersections were looked for. The number of tendinous intersections in each case was studied in all 41 cadavers. Since many recti were damaged during the student dissection and their location with reference to xiphisternum, umbilicus and the pubic symphysis in each muscle could be studied in only 18 cadavers (36 recti), . The distance of these intersections from pubic symphysis, umbilicus and xiphisternal joint was measured to the nearest millimeter using a measuring tape. The following measurements concerning the dimensions of the rectus abdominis were also measured using a measuring tape to the nearest millimeter (in 18 cadavers i.e., 36 recti): a) total length of the muscle; b) Width of the muscle at the level of its origin, insertion, costal margin, umbilicus and the interval between the umbilicus and the pubic symphysis. Patterns of tendinous inscriptions were studied in 104 tendinous inscriptions of 18 cadavers according to the description given by Milloy, Anson and McAfee (four types) 1 was: Type A is the straight line, Type B and C are simple curved or angulated lines with apices directed caudad or cephalad; Type D is complex multiphasic type of inscription.

Results :

The results did not show any sexual or side dominance. The results are summarized below :

The dimensions of the rectus abdominis muscle:

The dimensions measured in the 36 recti muscles (18 cadavers) in the present study were as follows (mean and SD (range) in mms : total length - 335 ± 6.43 (270-375) ; width at different levels : origin - 65 ± 12.93 (40-85) ; insertion - 24 ± 5.8 (15-35) ; level-1 (at the costal margin) - 59.44 ± 8.73 (50-80) ; level-2 (at the level of the umbilicus) - 50.3 ± 9.7 (40-60) ; level-3 (below the umbilicus) - 48.05 ± 9.75 (40-70) .

Frequency of occurrence of the tendinous intersections :

The number of tendinous intersections varied from one to four and their frequency of occurrence was as follows (in eighty two recti) : the rectus muscle with four tendinous intersections were found in eighteen cases (21.95%) ; with three tendinous intersections were found in fifty cases (60.97 %) ; with two tendinous intersections were found in twelve cases (14.63%) and with only one inscription in two cases (2.44%) . The mean distance of the tendinous intersections from various landmarks on the anterior aspect of the trunk viz., the pubic symphysis, the umbilicus and the xiphisternum is shown in the Table-1.

Table-1 : Relative Distances of the Tendinous Intersections from Landmarks on the Anterior Wall of the Trunk

Tendinous intersections ↓ Land marks	Distances from Landmarks (mean and SD Cms)		
	Xiphisternum	Umbilicus	Pubic symphysis
First	5.785 ± 3.01	12.66 ± 3.71	27.98 ± 4.186
Second	12.355 ± 3.075	7.555 ± 3.33	22.485 ± 2.824
Third	18.095 ± 2.485	1.9935 ± 1.818	16.375 ± 2.636
Fourth	22.433 ± 1.388	4.23 ± 1.371	2.065 ± 1.221

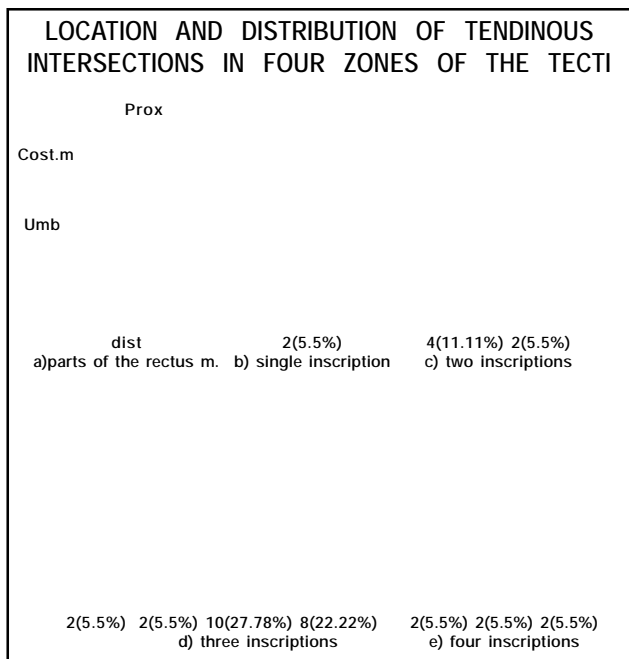


Fig - 1 shows the location and distribution of the tendinous inscriptions in four zones of the recti as observed in 18 cadavers.

LEGENDS FOR THE ILLUSTRATIONS :

Abbreviations used : cost.m-costal margin, dist-distal attachment (insertion) , prox-proximal attachment (origin) , umb-umbilicus. Numbers I, II, III, IV indicate the four zones of the muscle (see the text) .

Patterns of the tendinous inscriptions: The tendinous inscriptions were found to be adherent to the anterior wall of the rectus sheath and extended in to the substance of the muscle. The posterior wall was almost always free from adhesion to the inscriptions. The frequency of the four patterns in 104 tendinous inscriptions of 36 recti was as follows: A-49.04%; B&C-30.77%; D-10.58 %. Apart from these a fifth category of incomplete type was found in 9.6 %. In twelve cadavers (66.67%) the inscriptions were bilaterally symmetrical in pattern and in six (33.33%) the pattern was asymmetrical. In four cadavers (22.22%) all the inscriptions were bilaterally of

type A. In six cadavers (33.33%) either no I or the no III inscriptions were found to be incomplete i.e., they failed to reach either medial or lateral borders of the recti. In two (11.11%) of the cases the inscriptions were represented as patches close to one of the borders of the rectus.

Discussion :

The tendinous intersections also called "linea transversae" of the rectus abdominis vary in number between three to five, to some extent they limit fluid collections beneath the anterior sheath and prevent muscle rupture. By this arrangement the long muscle is divided into a number of shorter ones thus increasing its strength and efficiency.^{1,5} These intersections may represent the segmental origin of the muscle and the segments are supplied by different segmental nerves.⁴

Their attachments to the anterior sheath prevent the retraction of the rectus in transverse incision. A transverse rectus wound, in healing, forms essentially a new cross intersection. As there are hardly any studies in the Indian literature which specifically addresses the location of the tendinous intersections, hence this study has been undertaken.

According to Anson and McVay the division of the rectus muscle by inscriptions and related pattern of arterial supply are subject to great variations.¹ Among 162 recti (81 cadavers) studied by these authors at least one inscription was present in every case but none more than four; two one inscription (1%), nine two inscriptions (6%), ninety four three inscriptions (58%), fifty seven four inscriptions (35%) were seen and the number was same bilaterally. ¹ Wetzel and Huang dissected fourteen adult cadavers for the purpose of defining the arterial vascular anatomy of the

tendinous intersections of the rectus abdominis muscle. Three to four tendinous intersections could be identified in each rectus abdominis muscle. Twelve out of fourteen muscles (86%) had three intersections.⁶ The tendinous intersections were commonly seen at the level of the costal margin (superior), halfway between the costal margin and umbilicus (middle), and in the region of the umbilicus (inferior). The inferior intersection was frequently incomplete, extending from one-half to three fourths of the transverse distance across the rectus abdominis muscle. Two recti had a small rudimentary fourth intersection below the inferior transection.⁶

In the present study, 21.95% had four intersections; 60.97% had three intersections and 14.63% had two intersections and only two had single inscription (2.44%).

All inscriptions do not extend across the entire width of the muscles; in the study by Anson and McVay 530/356 (67%) were complete inscriptions extending from lateral to medial; one hundred and twenty eight were not complete but extended across more than half the width; forty six (9%) less than half the width. Of the forty six majority touched the lateral border.¹

Milloy, Anson and McAfee have classified the patterns of tendinous inscriptions into four types in their study of 289 inscriptions: Type A is the straight line, Type B and C are simple curved or angulated lines with apices directed caudad or cephalad; Type D was complex multiphasic type of inscription. They found an incidence of 21%, 50.5% and 28.4% for each of these types respectively. Incidence pattern of these types for 104 inscriptions studied in the present series was as follows: A-49.04%; B&C -30.77%;

D-10.58%. Apart from these a fifth category of incomplete type was found in 9.6%.⁷

Milloy, Anson and McAfee in their study divided the rectus muscle into four arbitrary zones: the first zone was the area of costal margin and above; the second area between the costal margin and the umbilicus; the third a narrow zone at the level of the umbilicus, and the fourth the area between the umbilicus and the tendon of insertion. These authors found that the most frequent location of the inscription was the second zone and often two inscriptions were found at this location. On the other hand no inscriptions were found in the fourth zone in over 50% of the muscles examined. Commonest number of inscriptions found on a muscle was three and these were located in zones I, II and III (38% of the recti examined).⁷ Location of the inscription in four zones of the thirty six recti (18 cadavers) examined in the present study is shown in the fig -1. The inscriptions were found most frequently in zone -II (100%), followed by zone I and zone III. In 16 recti (44.44%) inscriptions were found in zone IV.

The measurements of the recti in the present study were bilaterally symmetrical and there was no correlation between the length or width of the muscle and the number of inscriptions. Milloy, Anson and McAfee also found in their study the recti to be of equal length on two sides and measured between 34 to 38 centimeters.⁷

Das, Suri and Kapur in their study of the tendinous intersections of rectus abdominis muscle in 46 human cadaveric dissections over a span of 3 years, found only two unusual patterns of intersections: one with tendinous intersections arched, and the other with the intersections at different levels on the right and left sides of the same cadaver, were observed, in two different cadavers.⁸

Wetzel and Huang have studied the vascular anatomy of the tendinous intersections of the rectus abdominis muscle in fourteen adult cadavers. The superior epigastric artery commonly supplied the superior and middle intersections and the inferior epigastric artery commonly supplied the inferior intersection.⁶

The vascular architecture of the tendinous intersections is characterized by a system of transverse arcades arising from either deep superior epigastric artery or inferior epigastric artery to send branches supplying muscle or overlying skin. The intersections had a higher number of total perforators and large perforators per square centimeter than any of the rectus muscle segments. The greatest density of perforators (1.47/cms²) and large perforators (0.90/ cms²) occurred in the periumbilical inferior tendinous intersection. The muscle segment located in the superior periumbilical region had the highest concentration of perforators and large perforators of all the four muscle segments.⁶

Neurovascularized free RAM grafts are being extensively used in reconstruction of the breast, thorax, vagina, pelvic floor, anterior skull base, bladder, extremity defects.⁹⁻¹⁵ RAM grafts are even being used dynamic reanimation of facial paralysis.¹⁶⁻¹⁸ The TRAM flap is an important reconstructive tool, particularly in reconstruction of the breast following mastectomy. In clinical experience with TRAM flaps, it is seen that there is significant vascularity of the tendinous intersections, as witnessed by the amount of bleeding in these areas during dissections.⁶ Rectus abdominis musculo-peritoneal (RAMP) flap are also used for repair of duodenal fistulae.¹⁹ Janou et al., find the RAM flap to be the most promising myoplasty muscle for stomal sphincter reconstruction for several reasons, ie, its close proximity to the lower

abdominal quadrants, being long, broad muscle it can provide adequate muscle length for a circumferential wrap around the stoma, it has a reliable and consistent blood supply from the inferior epigastric artery, dissection can be performed through the same laparotomy incision, associated with minimal donor site morbidity.²⁰

Hartrampf and Michelow noted that the intersections may not extend completely through the substance of the muscle, and when this occurs, the deep epigastric vessels pass between the segments while remaining within the muscle. They stated that the deep epigastric vessels course behind the muscle in the upper and lower portions but then enter the muscle and pass through the two tendinous intersections that are situated at and above the level of umbilicus to anastomose within that segment of that muscle which lies between them. Because the anterior sheath is rigidly adherent to the intersections, attempts to dissect the sheath free at these two levels place the vessels within the rectus at risk.²¹ In this study the intersections did not extend completely through the substance of the muscle. Boyd, Taylor and Corlett noted that the highest concentrations of perforators in the paraumbilical area and an increased density of large perforators in the tendinous intersections.²² Whetzel and Huang have also found an increased density of perforating arteries at the intersection. Better understanding of the location of the tendinous intersection may allow for development of surgical techniques to improve circulation to TRAM flaps.⁶

References :

1. Anson BJ and McVay CB. eds. part IV: Abdomen; Chapter 4: Abdominal wall. In *Surgical Anatomy* 5th Edition. Philadelphia, London, Toronto :WB Saunders Co. 1971: p 461-478.

2. Cullin TS and Brodel M Lesions of the rectus abdominis simulating an acute intra abdominal condition. *Bull Johns Hopkins Hosp.* 1937;**61**:295-348.
3. Hollinshead HW ed. Volume-2. In Chapter-5: The Abdominal Wall and Inguinal Region. In : *Anatomy for Surgeons*, New York : *Hoeber and Harper*. 1956:p 217-266.
4. Sinnatamby CS.ed. Last's Anatomy, Regional and Applied, 10th Edition. London, NewYork, Philadelphia, Sydney, Toronto : *Churchill and Livingstone*. 1999:p 215-226.
5. Thorek P. ed. Sec.IV-The Abdomen, Chapter-22: Abdominal wall. In:*Anatomy in Surgery*. Philadelphia, Montreal: *JB Lippincott Co*. 1958:p 363-3.
6. Whetzel TP and Huang H. The vascular anatomy of the tendinous intersections of the rectus abdominis muscle. *Plast Reconstr Surg.* 1996;**98(1)** : 83-89.
7. Milloy FJ, Anson BJ and McAfee D. The rectus abdominis muscle and the epigastric arteries. *Surg Gynecol Obstet.* 1960;**110**: 293-302
8. Das S, Suri RK, Kapur V. Clinical importance of unusual patterns of tendinous intersections of rectus abdominis muscle. *Nepal Med Coll J.* 2003: **5(2)**:87-8.
9. Reath DB, Taylor JW.Free rectus abdominis muscle flap : advantages in lower extremity reconstruction. *South Med J.* 1989 Sep: **82(9)**:1143-6
10. Nishimoto S, Kakibuchi M, Hosokawa K, Maeda M, Urakawa S,Hikasa H,Tsukino A, Maeda FJ. Free rectus abdominis musculocutaneous flap for head and neck reconstruction. *Reconstr Microsurg.* 1997 Apr:**13(3)** :171-5.
11. Giampapa V, Keller A, Shaw WW, Colen SR. Pelvic floor reconstruction using the rectus abdominis muscle flap. *Ann Plast Surg.* 1984 Jul:**13(1)**:56-9.
12. Benson C, Soisson AP, Carlson J, Culbertson G, Hawley-Bowland C,Richards F. Neovaginal reconstruction with a rectus abdominis myocutaneous flap. *Obstet Gynecol.* 1993 May:**81(5 (Pt 2)**):871-5.
13. Rectus abdominis muscle-musculocutaneous flap in chest-wall reconstruction. Coleman JJ 3rd,Bostwick J. *Surg Clin North Am.*1989 oct: **69(5)** : 1007-27.
14. Zhang YH, Shao QA, Wang JM. Enveloping the bladder with displacement of flap of the rectus abdominis muscle for the treatment of neurogenic bladder. *J Urol.* 1990Nov: **144(5)**:1194-5.
15. Zing -Quan Z, Shao-Dong W, Quing-Yu F, Bao- An M. Versatility of rectus abdominis free flap for reconstruction of soft tissue defects in extremities. *Microsurgery.* 2004:**24(20)**:128-33.
16. Hata Y, Yano k, Matsuka K, Ito O, Matsuda H, Hosokawa K. Treatment of chronic facial palsy by transplantation of the neurovascularized free rectus abdominis muscle. *Plast Reconstr Surg.* 1990 Dec:**86(6)** : 1178-87; discussion 1188-9.
17. Takushima A, Harii K, Asato H, Ueda K, Yamada A Neurovascular free- muscle transfer for the treatment of established facial paralysis following ablative surgery in the parotid region.. *Plast Reconstr Surg.* 2004 May:**113(6)** :1563-72.
18. Terzis JK, Noah ME. *Plast Reconstr Surg.* 1997 Jun;99(7) :1905-21. Comment in : *Plast Reconstr Surg.*1998. Feb:101(2) :554-5. Analysis of 100 cases of free- muscle transplantation for facial paralysis.
19. Agarwal P and Sharma D. Repair of duodenal fistula with rectus abdominis musculo-peritoneal (RAMP) flap. *Indian J Gastroenterol.* 2004:**23(4)** : 143-4.
20. Bardoel JWJM, Stadelman WK, Tobin GR, Werker PMN, Stremel RW, Kon M, Barker JH. Use of rectus abdominis muscle for abdominal stoma sphincter construction : an anatomical feasibility study. *Plast Reconstr Surg.* 2000 Feb : **105(2)** : 589-595.
21. Hartrampf CR., Jr.and Michelow BJ. Anatomy of the Anterior Abdominal Wall in Hartrampf CR., Jr.and Michelow BJ (eds), *Hartrampf 's Breast Reconstruction with Living Tissue*. Norfolk, Va: Hampton Press. 1991. Quoted by Whetzel TP and Huang H 6
22. Boyd JB, Taylor GI and Corlett R The vascular territories of the superior epigastric and the deep inferior epigastric systems. *Plast Reconstr Surg.* 1984: **73**:1.